PrepBlink Your Potential Unlocked

PYQSide

PYQSide.com — free PYQs with solutions

NEET STRUCTURAL ORGANISATION IN ANIMALS — EPITHELIAL TISSUE — PYQS

Max. Marks: 80 **Questions:** 20

Section A (MCQ) — 20 questions

1. Match **List I** with **List II**:

List - I		List - II	
A.	Unicellular glandular epithelium	I.	Salivary glands
B.	Compound epithelium	II.	Pancreas
C.	Multicellular glandular epithelium	III.	Goblet cells of alimentary canal
D.	Endocrine glandular epithelium	IV.	Moist surface of buccal cavity

Choose the correct answer from the options given below: [NEET (UG) 2024]

(1) A-II, B-I, C-III, D-IV
(2) A-IV, B-III, C-I, D-II
(3) A-III, B-IV, C-I, D-II
(4) A-II, B-I, C-IV, D-III

Scan or tap for the full solution

2. Which of the following statements is correct about the type of junction and their role in our body? [RE-NEET (UG) 2024]

(1) Adhering junctions facilitate the cells to communicate with each other.
(2) Tight junctions help to stop substances from leaking across a tissue.
(3) Tight junctions help to perform cementing to keep neighbouring cells together.
(4) Gap junctions help to create gap between the cells and tissues.

Scan or tap for the full solution

3. Match **List I** with **List II** :

List - I		List - II	
A.	Squamous Epithelium	I.	Goblet cells of alimentary canal
B.	Ciliated Epithelium	II.	Inner lining of pancreatic ducts
C.	Glandular Epithelium	III.	Walls of blood vessels
D.	Compound Epithelium	IV.	Inner surface of Fallopian tubes

Choose the correct answer from the options given below : [RE-NEET (UG) 2024]

(1) A-II, B-III, C-I, D-IV
(2) A-II, B-IV, C-III, D-I
(3) A-III, B-I, C-II, D-IV
(4) A-III, B-IV, C-I, D-II

Scan or tap for the full solution

4. Which of the following types of epithelium is present in the bronchioles and Fallopian tubes? [NEET (UG) 2022 (Phase 2)]

(1) Stratified squamous epithelium
(2) Simple squamous epithelium
(3) Simple columnar epithelium
(4) Ciliated epithelium

Scan or tap for the full solution

5. Identify the types of cell junctions that help to stop the leakage of the substances across a tissue and facilitation of communication with neighbouring cells via rapid transfer of ions and molecules. [NEET (UG) 2021]

(1) Adhering junctions and Gap junctions, respectively
(2) Gap junctions and Adhering junctions, respectively
(3) Tight junctions and Gap junctions, respectively
(4) Adhering junctions and Tight junctions respectively

Scan or tap for the full solution

6. Cuboidal epithelium with brush border of microvilli is found in [NEET (UG) 2020]

(1) Ducts of salivary gland
(2) Proximal convoluted tubule of nephron
(3) Eustachian tube
(4) Lining of intestine

Scan or tap for the full solution

7. Goblet cells of alimentary canal are modified from [NEET (UG) 2020]

(1) Columnar epithelial cells
(2) Compound epithelial cells
(3) Squamous epithelial cells
(4) Chondrocytes

Scan or tap for the full solution

8. The ciliated epithelial cells are required to move particles or mucus in a specific direction. In humans, these cells are mainly present in: [NEET (UG) 2019]

(1) Eustachian tube and Salivary duct
(2) Bronchioles and Fallopian tubes
(3) Bile duct and Bronchioles
(4) Fallopian tubes and Pancreatic duct

Scan or tap for the full solution

9. The function of the gap junction is to - [AIPMT 2015]

(1) facilitate communication between adjoining cells by connecting the cytoplasm for rapid transfer of ions, small molecules and some large molecules.
(2) separate two cells from each other
(3) stop substance from leaking across a tissue
(4) performing cementing to keep neighbouring cells together

Scan or tap for the full solution

10. Choose the correctly matched pair: [AIPMT 2014]

(1) Inner surface of bronchioles - squamous epithelium
(2) Moist surface of buccal cavity - Glandular epithelium
(3) Inner lining of salivary ducts - Ciliated epithelium
(4) Tubular parts of nephrons - Cuboidal epithelium

Scan or tap for the full solution

11. The four sketches (A, B, C and D) given below, represent four different types of animal tissues. Which one of these is correctly identified in the options given, along with its correct location and function ? [AIPMT 2012 (Mains)]

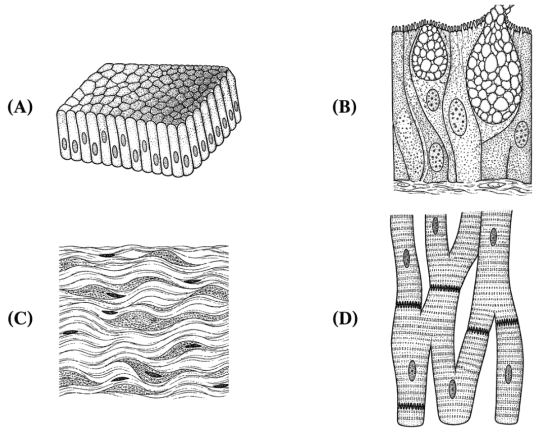

(1) (A) Tissue ⟶ Columnar epithelium, Location ⟶ Nephron, Function ⟶ Secretion and absorption
(2) (C) Tissue ⟶ Collagen fibres, Location ⟶ Cartilage, Function ⟶ Attach skeletal muscles to bones
(3) (B) Tissue ⟶ Glandular epithelium, Location ⟶ Intestine, Function ⟶ Secretion
(4) (D) Tissue ⟶ Smooth muscle tissue, Location ⟶ Heart, Function ⟶ Heart contraction

Scan or tap for the full solution

12. The cells lining the blood vessels belong to the category of : [AIPMT 2011 (Mains)]

(1) Squamous epithelium
(2) Columnar epithelium
(3) Connective tissue
(4) Smooth muscle tissue

Scan or tap for the full solution

13. The ciliated columnar epithelial cells in humans are known to occur in : [AIPMT 2011 (Prelims)]

(1) Eustachian tube and stomach lining
(2) Bile duct and oesophagus
(3) Fallopian tubes and urethra
(4) Bronchioles and Fallopian tubes

Scan or tap for the full solution

14. The cells lining the blood vessels belong to the category of : [AIPMT 2010 (Prelims)]

(1) Columnar epithelium
(2) Connective tissue
(3) Smooth muscle tissue
(4) Squamous epithelium

Scan or tap for the full solution

15. The epithelial tissue present on the inner surface of bronchioles and fallopian tubes is : [AIPMT 2009]
(1) Cuboidal (2) Glandular
(3) Ciliated (4) Squamous

Scan or tap for the full solution

16. The cell junctions called tight, adhering and gap junctions are found in : [AIPMT 2009]
(1) Connective tissue (2) Neural tissue
(3) Epithelial tissue (4) Muscular tissue

Scan or tap for the full solution

17. In which one of the following preparations are you likely to come across cell junctions most frequently? [AIPMT 2007]
(1) Thrombocytes (2) Tendon
(3) Hyaline cartilage (4) Ciliated epithelium

Scan or tap for the full solution

18. Bowman's glands are found in [AIPMT 2006]
(1) juxtamedullary nephrons
(2) olfactory epithelium
(3) external auditory canal
(4) cortical nephrons only

Scan or tap for the full solution

19. Melanin protects from: [AIPMT 2002]
(1) Infrared rays (2) U.V. rays
(3) Visible rays (4) X-rays

Scan or tap for the full solution

20. Characteristic of simple epithelium is that they [AIPMT 2000]
(1) Continue to divide and help in organ function
(2) They are arranged indiscriminately
(3) They make a definite layer
(4) None

Scan or tap for the full solution

ANSWER KEY

Ques.	1	2	3	4	5	6	7	8	9	10	11
Ans.	**3**	**2**	**4**	**4**	**3**	**2**	**1**	**2**	**1**	**4**	**3**
Ques.	12	13	14	15	16	17	18	19	20		
Ans.	**1**	**4**	**4**	**3**	**3**	**4**	**2**	**2**	**3**		